

Severity and Patterns of COVID-19 Among Sudanese Patients Using High Resolution Computed Tomography: Jabra Isolation Centre Based Study

Abdulaziz Hussein*, Saida Abdalkreem, Duha Abdu, Abdelmonem Adam, Mohammed Khalifa, Aseif Abdalla, Sayd Ahmed Mohammed, Ahmed Balil

College of Medical Radiological Science, Sudan University of Science and Technology, Khartoum, Sudan

Email address:

Azooahmed93@gmail.com (A. Hussein), Saidaabdelkreem@gmail.com (S. Abdalkreem), Duha@gmail.com (D. Abdu), abdelmonemadam1997@gmail.com (A. Adam), Khalifamhmd22@gmail.com (M. Khalifa), assifabdalla96@gmail.com (A. Abdalla), sydahmdmhmd769@gmail.com (S. A. Mohammed)

*Corresponding author

To cite this article:

Abdulaziz Hussein, Saida Abdalkreem, Duha Abdu, Abdelmonem Adam, Mohammed Khalifa, Aseif Abdalla, Sayd Ahmed Mohammed, Ahmed Balil. Severity and Patterns of COVID-19 Among Sudanese Patients Using High Resolution Computed Tomography: Jabra Isolation Centre Based Study. *International Journal of Medical Imaging*. Vol. 10, No. 2, 2022, pp. 22-28. doi: 10.11648/j.ijmi.20221002.13

Received: May 19, 2022; Accepted: June 1, 2022; Published: June 8, 2022

Abstract: *Background:* Following the emergence of COVID-19, chest CT exams were utilized as a supplement to RT-PCR for diagnosis and follow-up when RTPCR findings became unavailable. *Aims:* characterize the patterns and severity of COVID-19 using high resolution computed tomography among Sudanese patients in Jabra Isolation Center, Khartoum State. *methods and Materials:* A total of 50 patients having COVID-19 who had chest CT and were confirmed positively by RT-PCR were involved in this study. clinical and laboratory data were collected by reviewing the hard medical records. radiology abnormalities were categorized based upon the patterns and distribution within the lungs. The CT-SS was determined by adding individual scores from each of the six lung regions; rated by Likert scale as 0 (0%), 1 (1–25%), 2 (26–50%), 3 (51–75%), or 4 (76–100%). The total severity score was reached by summing the sex lobe scores into mild and severe cases. *Results:* (33 were men and 17 were women, 26 patients have more than 60 years, they were the majority age group, There were 28 cases of mild and 22 cases of severe disease). Study found that (COVID-19) was distributed as Multi-lesions in 46 cases (92%), bilaterally, and diffused within the lung fields in (39,77%, 41,81% respectively). Peripheral ground glass opacities patterns (GGOs) were the most domain feature. There was a significant difference in distribution of disease between right and left lungs ($p < 0.05$). Where the right lung was the most infected in both mild and severe cases. The lower lobes of both lungs were the most involved sites by COVID-19 in compare with the upper and middle lobes in both lungs. *Conclusions:* In COVID-19, thin-section high-resolution chest CT is a critical medical imaging tool for detecting the lung parenchymal diseases. Semi-quantitative CT scoring system can be used to assess the severity of lung involvement rapidly and effectively.

Keywords: COVID-19, HRCT, Ground Glass Opacities, CT Scoring System

1. Introduction

COVID-19 (Corona Virus Disease 2019) is a rapidly and infectious spreading viral disease caused by Severe Acute Respiratory Syndrome (SARS). Corona Virus (SARS-CoV-2) is an RNA virus which resembles a crown. It is primarily spread from one person to another via respiratory droplets. [1].

The World Health Organization (WHO) reported numerous cases of viral pneumonia with an unknown origin in Wuhan, Hubei Province, China, on December 31, 2019. As of March 22, 2022, there had been 470 839 745 confirmed cases and 6092 933 confirmed deaths worldwide [2].

COVID-19 has infected millions of people worldwide and continues to pose a real threat to millions more [3]. has

reached Sudan on mid of March 2020, and by the end of March 2022 there are 61,842 confirmed cases and 4,897 total deaths [4]. The major clinical presentation of COVID-19, such as cough, fever, fatigue, and dyspnea, can help in early disease detection and preventing it from spreading to others. clinical, laboratory, and radiologic parameters are used to classify COVID-19 severity [5, 6].

Real-time reverse transcriptase-PCR (RT-PCR) is getting popular for testing SARS-CoV-2 because of its advantages as a specific and simple qualitative test [7].

Chest CT scan have a crucial role in the diagnosing and follow-up of patients who infected with COVID-19. The radiographic abnormalities changes in the acute course of COVID-19 have been reported in a variety of investigations, ranging from mild to severe cases [8, 9].

So, The combination of real-time RTPCR and clinical features, especially CT imaging, can make disease management easier (10).

A high-resolution CT severity score system was widely used for medical decision-making and prognosis in interstitial lung disease and pneumonia [11, 12]. As well as, The chest CT findings of COVID-19 are reported in a variety of literatures as multiple ground glass opacity, consolidation, and interlobular septal thickening in both lungs, which are predominantly dispersed beneath the pleura [13].

However, because there have been few published investigations in this area in Sudan, this work might be the first to use high-resolution computed tomography to assess COVID-19 patterns and severity. As a result, the authors believe that our findings would be useful in establishing a local standard for COVID-19 patterns and severity among Sudanese patients in Jabra Isolation Center, Khartoum State.

2. Material and Methods

The study was approved by the diagnostic radiology department, college of medical radiological science, Sudan university of science and technology and Khartoum state ministry of health under number (WKH/WS/1ATAA/44/A). This was conducted at a single-center, retrospective, observational study between September 21, 2021 and February 13, 2022 at Jabra Isolation center. This hospital was chosen because it is Sudan's first and largest COVID-19 isolation center, as well as an international center accredited by the Federal Ministry of Health and the World Health Organization. This study included 50 adult patients who tested positive for COVID-19 infection by real-time reverse transcriptase polymerase chain reaction (rRT-PCR) and performed a chest HRCT scan, excluding those with lung cancer, a history of lobectomy, tuberculosis, or atelectasis. Patients' medical record names were hidden from data handlers while demographic data, clinical presentations, and medical histories were collected. Two radiologists with more than three years of experience independently assessed HRCT radiographic images while being blinded to the patients' clinical data. The cross sectional radiographic HRCT images were independently assessed, and the final decisions were

made by consensus. The abnormal features of chest HRCT imaging were quantitatively evaluated. Two radiologists evaluated the abnormal imaging findings (Single, Multiple, Uni-lateral, Bi-lateral, Localized, Diffused, Patchy, Nodular, Peripheral Ground Glass Opacities (GGOs), Consolidation, interlobular septal thickening, and Sub-plural band). COVID-19-related lymphadenopathy, pulmonary fibrosis, pleural effusion, and emphysema were all ruled out. The radiologists calculated the lesion areas on each lung lobe as a percent of the overall lung lobe area. The lung was divided into six zones by the level of tracheal carina and the level of inferior pulmonary vein bilaterally on CT images, and the percentages in each lung lobe were scored using a semi-quantitative visual scoring system (CT-SS) to identify the severity of COVID-19 disease. GGOs (ground-glass opacities) were assessed on a 0–4 Likert scale. (0 = absent; 1 = 1 – 25%; 2 = 26 – 50%; 3 = 51 – 75%; 4 = 76 – 100%). The cumulative score of six zones has been used to compute the global severity score for each targeted pattern (24). Mild cases are those with 1 to 12 total scores, while severe cases are those with 13 to 24 total scores.

All CT scans were performed with all patients in the supine position and holding their breath at the end of inhalation. The scan parameters are: Tube voltage 120 kV, tube current 110 mA, pitch 1.0, rotation time 0.5 s to 0.75 s, slice thickness 5 mm, slice thickness 1 mm or 1.5 mm for axial reconstruction, coronal sagittal reconstruction with 64 slices of spiral computed tomography scanner (TOSHIBA Aquilion CT unit) installed in 2012.

3. Statistical Analysis

Statistical Products and Services software was used to conduct all statistical analyses (SPSS Statistics, version 26.0, Chicago, IL, USA). Statistical significance was defined as a value of 0.05. The cross tabulation statistic is used to represent categorical data as frequencies and percentages. The weighted kappa coefficient was used to examine the consistency of two observers in each lung lobe, and Fisher's exact test was applied to compare scores of each lung lobe between the mild and severe groups. To find significant differences, use the mean and student's t-test to compare the left and right lung scores, upper lobe scores, middle lobe scores, and lower lobe scores.

4. Results

There were 33 (66%) men and 17 (34%) women. Ages were categorized into three groups, the majority of patients over 60 years of age 26 (52%) and 20 (40%) between 40 and 59 years of age. Depending on signs and symptoms, patients with cough, fever, hypoxemia and SOB were the common clinical presentations (29; 58%, 28; 56%, 14; 28% and 13; 26%, respectively). The prevalence of hypertension and diabetes was (18; 36% and 18; 36%). COVID-19 was distributed as multiple lesions in 46 (92%) cases, bilateral and diffuse in (39; 77%, 41; 81%, respectively) in the lung field, having patchy

pattern in 42 (84%) cases. ground glass opacity (GGO) was found in 46 (92%) cases. Consolidation are found in 20 (40%) cases. The sample was divided into two groups; Mild cases were 28 (56%) and severe cases were 22 (44%). There was a significant difference between the lung opacity scores of the

mild group and the severe group in each lung lobe ($P < 0.05$), in which the right lung was infected the most in the mild and severe group with the mean value (4.46; 8.68) compared with the left lung (2.96; 8.00, respectively) with the significant difference in the two comparisons ($P = 0.00$).

Table 1. Demographic and Clinical Data of 50 Patients with COVID-19.

Variables		CT-SS	
		Mild (n=28) (N;%)	Severe (n=22) (N;%)
Gender	Total (n = 50) (%)		
Male	33 (66%)	(17; 60.71%)	(16; 72.72%)
Female	17 (34%)	(11; 39.28%)	(6; 27.27%)
Age			
20-39 years	4 (8%)	(3; 10.71%)	(1; 4.45%)
40-59 years	20 (40%)	(10; 35.71%)	(10; 45.45%)
More than 60 years	26 (52%)	(15; 53.57%)	(11; 50.00%)
Clinical Presentations			
SOB	13 (26%)	(20; 71.42%)	(17; 77.27%)
Chest pain	3 (6%)	(2; 7.14%)	(1; 4.45%)
Fever	28 (56%)	(14; 50.00%)	(14; 63.63%)
Cough	29 (58%)	(16; 57.14%)	(13; 59.09%)
Headache	6 (12%)	(1; 3.57%)	(5; 22.72%)
Fatigue	13 (26%)	(6; 21.42%)	(7; 31.81%)
Hypoxia	14 (28%)	(10; 35.71%)	(4; 18.18%)
Medical History			
Hypertension	18 (36%)	(10; 35.71%)	(8; 36.36%)
DM	18 (36%)	(11; 39.28%)	(7; 31.81%)
No Dis	9 (18%)	(3; 10.71%)	(1; 4.45%)
CHD	5 (10%)	(0; 00.00%)	(1; 4.45%)

Table 2. Final radiographic images diagnoses of HRCT.

Variables		Disease severity, n (%)		P value
		Mild (n=28)	Severe (n=22)	
Lesion Number	Single	(4; 14.28%)	(0; 00.00%)	0.065
	Multi	(24; 85.71)	(22; 100%)	
Uni-lateral		(9; 32.14%)	(0; 00.00%)	0.003
Bi-lateral		(17; 60.71%)	(22; 100%)	0.001
Localized		(8; 28.57%)	(0; 00.00%)	0.006
Diffused		(19; 67.85%)	(22; 100%)	0.003
Nodular		(6; 21.42%)	(3; 13.63%)	0.477
Patchy		(22; 78.57%)	(20; 90.90%)	0.238
Peripheral GGOs		(25; 89.82%)	(21; 95.45%)	0.425
Sub-plural band		(3; 10.71%)	(0; 00.00%)	0.113
Consolidation		(7; 25.00)	(13; 59.09%)	0.015
Inter-lobular septal Thickness		(4; 14.28%)	(0; 00.00%)	0.065
Using cross tabulation, Chi square				

Table 3. Comparison of scores of each lung lobes between the two severity groups.

Lung Lobe	Frequency (n=50)	Mild (n=28)	Severe (n=22)	P Value	Kappa
Left Upper Lobe (LUL)					
0	17	15 (53.57%)	1 (4.54%)	0.000	0.86
1	22	12 (42.58%)	10 (45.45%)		
2	7	0 (0.00%)	7 (31.81%)		
3	3	0 (0.00%)	3 (13.63%)		
4	1	0 (0.00%)	1 (4.54%)		
Left Middle Lobe (LML)					
0	6	5 (17.85%)	0 (0.00%)	0.000	0.73
1	15	15 (53.57%)	0 (0.00%)		
2	13	7 (25.00%)	6 (27.27%)		
3	11	0 (0.00%)	11 (50.00%)		
4	5	0 (0.00%)	5 (22.72%)		

Lung Lobe	Frequency (n=50)	Mild (n=28)	Severe (n=22)	P Value	Kappa
Left Lower Lobe (LLL)					
0	6	5 (17.85%)		0.000	0.80
1	9	8 (32.00%)	1 (4.54%)		
2	9	9 (32.14%)	0 (0.00%)		
3	15	4 (14.28%)	11 (50.00%)		
4	11	1 (3.57%)	10 (45.45%)		
Right Upper Lobe (RUL)					
0	7	5 (17.85%)	2 (9.09%)	0.017	0.66
1	20	14 (50.00%)	5 (22.72%)		
2	13	7 (25.00%)	6 (27.27%)		
3	3	0 (0.00%)	3 (13.63%)		
4	7	1 (3.57%)	6 (27.27%)		
Right Middle Lobe (RML)					
0	4	3 (10.71%)	0 (0.00%)	0.000	0.79
1	11	10 (53.71%)	1 (4.54%)		
2	18	12 (42.85%)	6 (27.27%)		
3	7	1 (3.57%)	6 (27.27%)		
4	10	1 (3.57%)	9 (40.90%)		
Right Lower Lobe (RLL)					
0	2	1 (3.57%)	0 (0.00%)	0.000	0.90
1	8	7 (25.00%)	1 (4.54%)		
2	12	11 (39.28%)	1 (4.54%)		
3	14	5 (17.85%)	9 (40.90%)		
4	14	3 (10.71%)	11 (50.00%)		

5. Discussion

On January 30, 2020, the World Health Organization declared COVID-19 to be the sixth public health emergency pandemic requiring worldwide concern [14]. COVID-19 is a highly contagious viral disease that has spread around the world [15]. Furthermore, if there are no early abnormalities on the chest x-ray, a significantly number of false negatives can occur [16]. Whenever it comes to detect the pathological alterations in the pulmonary parenchyma early in the illness process, thin-section chest CT is more sensitive than chest radiography [17]. As a result, during in the COVID-19 outbreak in China, chest CT has become a major diagnostic imaging tool [16].

This study was aimed to characterize the patterns and severity of COVID-19 using high resolution computed tomography scan. A total of 50 patients who had Chest (HRCT) and confirmed positively with COVID-19 using RT-PCR were included in this study.

According to the findings of this study, males are more likely than females to be infected with COVID-19, whether in mild or severe cases. These findings are in line with recent research, which suggests that higher levels of ACE2 and TMPRSS2 in males, hormonal influences on the immunological response, and gender variations in behavior may all have a role in the greater severity and fatality of COVID-19 seen in men [17].

Older adults and persons with underlying medical conditions are at higher risk for infected with severe COVID-19 [18]. Study showed that patients who have age over 60 years, were more likely to be infected with COVID-19 than

those under the age of 39. As a result, According to the Centers for Disease Control and Prevention (CDC), older people are more likely to become very ill as a result of COVID-19. Elderly people with COVID-19 who are seriously ill may require hospitalization, intensive care, or a ventilator to help them breathe, or they may die. People in their 50s are at higher risk, as are those in their 60s, 70s, and 80s. People aged 85 and up have a higher risk of becoming seriously ill. [19].

We also observed that cough, fever, hypoxia, and SOB were the most common clinical manifestations associated with COVID-19 infection, as many literatures state that common clinical symptoms of COVID-19 patients include fever, cough, dyspnea, and fatigue, which are similar to those of severe acute respiratory syndrome coronavirus (SARS-CoV) and Middle East respiratory syndrome coronavirus (MERS-CoV) [20, 21, 22].

Our patient had a prevalence of hypertension and diabetes of cases (18; 36%). These results are consistent with previous studies, which suggested that these findings may be related to the advanced age of the patients. The relationship between cardiovascular comorbidities and clinical severity and prognosis in hospitalized patients needs further investigation, as it will have a significant impact on patient care [23].

Imaging features

Typical patterns of early COVID-19 are round, patchy segmented, or segmented ground glass opacities with or without consolidation [24]. Lesions are multiple and distributed asymmetrically and are more common in the peripheral regions [10]. In this study, the imaging patterns were consistent with the previous literature reports (16-18) of viral pneumonia; Study found that COVID-19 distributed as multi-lesions in (92%) cases, bilaterally and diffused in (77%),

81%, respectively) within the lung fields, having patchy pattern in (84%) cases. ground glass opacity (GGOs) was the most common feature in this descriptive cross-sectional study which found in (92%) cases. Consolidation have found in 20 (40%) cases. These findings in the same line with previous study which state the predominant imaging pattern was of a peripheral ground- glass opacification with occasional consolidation in the peripheries [21, 25].

In correlation between (CT-SS) and the radiographic patterns, there was a significant difference ($P < 0.05$) according to uni-lateral, bi-lateral, localized, diffused and consolidation lesion in both mild and severe groups (0.003,

0,001, 0,005. Respectively).

Using a semi-quantitative scoring approach (CT Chest Scoring), the lung was divided into six zones (upper, middle, and lower on both sides) by the level of the tracheal carina and the level of the inferior pulmonary veins bilaterally on cross sectional CT images [9]. Using this Likert scale, the reviewers assessed the amount of the targeted patterns and the total affected lung parenchyma for each lobe. When comparing mild and severe cases, we discovered that the CT-SS was higher in severe cases. There were highly significant differences ($p < 0.05$) within lung lobes scores among the two severity groups (using Fisher exact test).

Table 4. Comparison of Left Lung Scores mean and Right Lung Scores mean, Upper Lobe Scores mean, Middle Lobes Scores mean and Lowe Lobe Scores mean ($n=50$).

Variables	Left lung	Right lung	P value	Upper Lobes	Middle Lobes	Lower Lobes	P value
Mild ($n=28$)	2.96	4.64	0.00	1.61	2.5	3.5	0.00
Severe ($n=22$)	8.00	8.68	0.00	3.95	5.95	6.52	0.00

When we compared the right lung score mean to the left lung score mean with the two severity groups using student' t-test, there was a significant difference ($P < 0.05$). also, the right lung was the most infected in both the mild and severe groups, with mean (4.46; 8.68, respectively), where left scores mean were (2.96; 8.00) as shown in table 4 above.

More than two lobes were affected in the majority of COVID-19 lesions [20, 21]. COVID-19 was most typically found in the lower lobes of both lungs, as compared to the upper and middle lobes in both lungs. Previous research [20] used a semi-quantitative scoring system to count the amount of lung opacification involving 20 lung regions as a surrogate for COVID-19 burden and discovered that the CT-SS was higher in severe cases when there was more lung opacification. It contradicts their conclusion that there are no significant changes in lung scores between the left and right lungs. and not consistent with their results, where they found there is insignificant differences between left and right lung scores.

6. Conclusion

The majority of COVID-19 patients with abnormal chest CT scans have ground glass opacities (GGOs). Bilateral opacities are more common in patients with severe illness and are associated to the severity of the disease. In COVID-19, thin-section high-resolution chest CT is an important medical imaging tool for detecting lung abnormalities. Semi-quantitative CT scoring system can be used to assess the severity of lung involvement rapidly and effectively.

7. Strength and Limitations

In Sudan, there have been insufficient published studies in this field. The study was completed at a critical time in the COVID-19 pandemic, when these studies are urgently needed.

This study had various limitations. First, the relatively small sample size was inadequate to disclose further potential

mechanism or to include other predictive factors for prognosis. The study's retrospective design may have resulted in selection bias. Another important problem was that lab testing and patient outcomes were not available in the majority of cases. In addition, characteristics such as cavitation and pleural effusion required further investigation. To validate the findings, bigger multi-center cohorts with follow- up and comprehensive data are required.

8. Recommendations

Future studies should use the RT-PCR results as the standard reference in conjunction with the final CT diagnose in order to determine the specificity and sensitivity (accuracy) as predictors for measuring disease severity. Since the clinical characteristics of COVID-19 change with the duration of the infection, we recommend future researchers to carefully consider the duration of disease as a fundamental factor in their studies.

Conflict of Interest

All the authors do not have any possible conflicts of interest.

Acknowledgements

The deepest gratitude to the supervisor *Dr. Saida Abdelkreem* for her encouragement, guidance and to co-supervisor *Dr. Salma Ibnomer* for her great support helped us in this research. As well as, the warmth gratitudes and thanks to Diagnostic Radiology Department staff in Sudan University of Sciences and Technology, College of Medical Radiological Science and to Jabra Isolation Center who facilitated to getting the sample of this work. Thanks to radiologist *Dr. Abdulrahman Hassan* and *Dr. Salah Alshoibi* for their analysis and constructive feedback on the cross sectional CT images.

Appendix

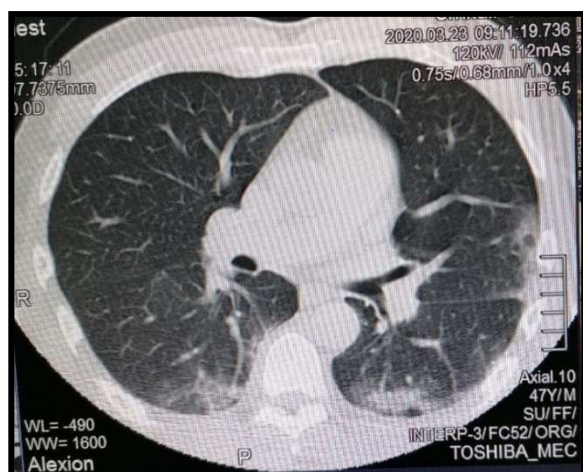


Figure 1. HRCT chest for male 47 years old show the first case recover from COVID-19 in Jabra Isolation center, Khartoum state, 23.03.2020.

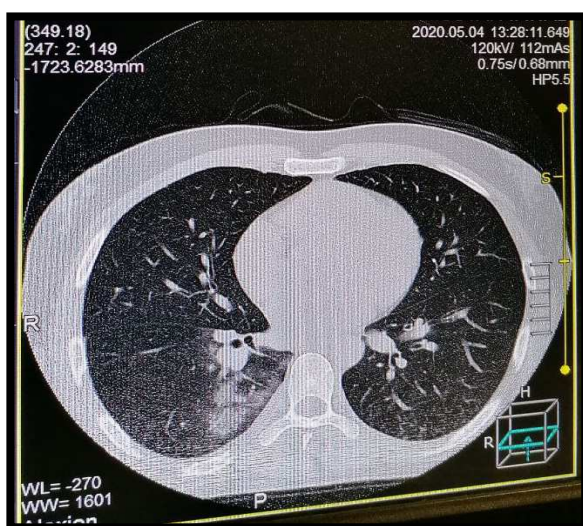


Figure 2. Noncontrast chest HRCT images in a 46-year-old man with mild COVID-19.

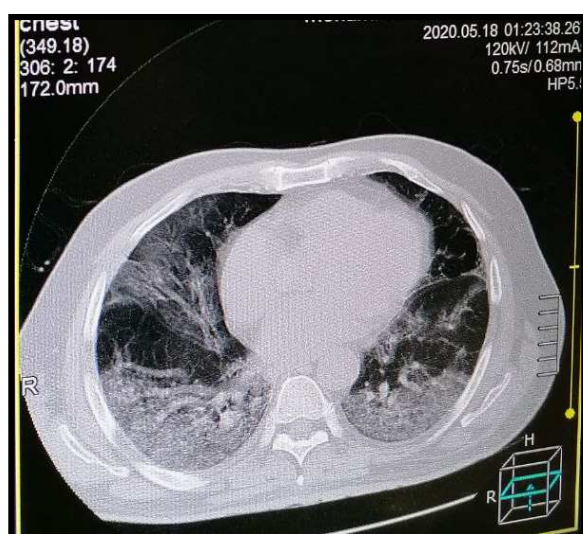


Figure 3. Noncontrast chest HRCT images in a 55-year-old woman with severe COVID-19.

References

- [1] Zhu N, Zhang D, Wang W, et al. A Novel Coronavirus from patients with pneumonia in China, 2019. *N Engl J Med* 2020; 382 (8): 727–733.
- [2] Li Q, Guan X, Wu P, et al. Early Transmission Dynamics in Wuhan, China, of Novel Coronavirus-Infected Pneumonia. *N Engl J Med* 2020 Jan 29 [Epub ahead of print].
- [3] Chinese Society of Radiology. Radiological Diagnosis of New Coronavirus Infected Pneumonitis: Expert Recommendation from the Chinese Society of Radiology (First edition). *Chin J Radiol* 2020; 54: E001.
- [4] Paul NS, Roberts H, Butany J, et al. Radiologic pattern of disease in patients with severe acute respiratory syndrome: the Toronto experience. *RadioGraphics* 2004; 24 (2): 553–563.
- [5] Mukherjee S, Pahan K. Is COVID-19 gender-sensitive? *Journal of Neuroimmune Pharmacology*. 2021 Mar; 16 (1): 38-47.
- [6] Assiri A, Al-Tawfi JA, Al-Rabeeh AA, et al. Epidemiological, demographic, and clinical characteristics of 47 cases of Middle East respiratory syndrome coronavirus disease from Saudi Arabia: a descriptive study. *Lancet Infect Dis* 2013; 13 (9): 752–761.
- [7] Lee N, Hui D, Wu A, et al. A major outbreak of severe acute respiratory syndrome in Hong Kong. *N Engl J Med* 2003; 348 (20): 1986–1994.
- [8] Baj J, Karakula-Juchnowicz H, Teresiński G, Buszewicz G, Ciesielka M, Sitarz E, Forma A, Karakula K, Flieger W, Portincasa P, Maciejewski R. COVID-19: Specific and Non-Specific Clinical Manifestations and Symptoms: The Current State of Knowledge. *J Clin Med*. 2020 Jun 5; 9 (6): 1753. doi: 10.3390/jcm9061753. PMID: 32516940; PMCID: PMC7356953.
- [9] Li S, Liu S, Wang B, Li Q, Zhang H, Zeng L, Ge H, Ma Q, Shen N. Predictive value of chest CT scoring in COVID-19 patients in Wuhan, China: a retrospective cohort study. *Respiratory Medicine*. 2021 Jan 1; 176: 106271.
- [10] Ng MY, Lee EYP, Yang J, et al. Imaging profile of the COVID-19 infection: radiologic findings and literature review. *Radiol Cardiothorac Imaging* 2020; 2 (1): e200034.
- [11] Lei J, Li J, Li X, Qi X. CT Imaging of the 2019 Novel Coronavirus (2019-nCoV) Pneumonia. *Radiology* 2020; 295 (1): 18.
- [12] Liu P, Tan XZ. 2019 Novel Coronavirus (2019-nCoV) Pneumonia. *Radiology* 2020; 295 (1): 19. 22.
- [13] Chung M, Bernheim A, Mei X, et al. CT imaging features of 2019 Novel Coronavirus (2019-nCoV). *Radiology* 2020; 295 (1): 202–207.
- [14] Jee, Youngmee. “WHO International Health Regulations Emergency Committee for the COVID-19 outbreak.” *Epidemiology and health* vol. 42 (2020): e2020013. doi: 10.4178/epih.e2020013.
- [15] Saleemi S, Alhajji M, Almaghrabi R. Clinical characteristics of patients with COVID-19 in Saudi Arabia-a single center experience. *Res Rev Infect Dis*. 2020; 3 (1): 68-74.

- [16] Ng MY, Lee EY, Yang J, Yang F, Li X, Wang H, Lui MM, Lo CS, Leung B, Khong PL, Hui CK. Imaging profile of the COVID-19 infection: radiologic findings and literature review. *Radiology: Cardiothoracic Imaging*. 2020 Feb 13; 2 (1): e200034.
- [17] Mukherjee, Shreya, and Kalipada Pahan. "Is COVID-19 Gender-sensitive?" *Journal of neuroimmune pharmacology: the official journal of the Society on NeuroImmune Pharmacology* vol. 16, 1 (2021): 38-47. doi: 10.1007/s11481-020-09974-z.
- [18] Jordan, Rachel E., Peymane Adab, and KK32217618 Cheng. "COVID-19: risk factors for severe disease and death." *Bmj* 368 (2020).
- [19] Centers for Disease Control and Prevention (CDC); available at: <https://www.cdc.gov/aging/covid19/covid19-older-adults.html#increased-risk> . Accessed on March 24, 2022. Last reviewed: August 2, 2021.
- [20] Yang R, Li X, Liu H, Zhen Y, Zhang X, Xiong Q, Luo Y, Gao C, Zeng W. Chest CT severity score: an imaging tool for assessing severe COVID-19. *Radiology: Cardiothoracic Imaging*. 2020 Mar 30; 2 (2): e200047.
- [21] Li K, Fang Y, Li W, Pan C, Qin P, Zhong Y, Liu X, Huang M, Liao Y, Li S. CT image visual quantitative evaluation and clinical classification of coronavirus disease (COVID-19). *Eur Radiol*. 2020 Aug; 30 (8): 4407- 4416. doi: 10.1007/s00330-020-06817-6. Epub 2020 Mar 25. PMID: 32215691; PMCID: PMC7095246.
- [22] Haseli S, Khalili N, Bakhshayeshkaram M, Sanei Taheri M, Moharramzad Y. Lobar Distribution of COVID-19 Pneumonia Based on Chest Computed Tomography Findings; A Retrospective Study. *Arch Acad Emerg Med*. 2020 Apr 18; 8 (1): e55. PMID: 32440666; PMCID: PMC7212068.
- [23] Gold JA, Wong KK, Szablewski CM, Patel PR, Rossow J, Da Silva J, Natarajan P, Morris SB, Fanfair RN, Rogers-Brown J, Bruce BB. Characteristics and clinical outcomes of adult patients hospitalized with COVID-19—Georgia, March 2020. *Morbidity and Mortality Weekly Report*. 2020 May 8; 69 (18): 545.
- [24] Gurumurthy, Balasubramanian et al. "Spectrum of atypical pulmonary manifestations of COVID-19 on computed tomography." *The Egyptian Journal of Radiology and Nuclear Medicine* vol. 52, 1 (2021): 72. doi: 10.1186/s43055-021-00448-7.
- [25] Rokaya Rehouma, Michael Buchert, Yi-Ping Phoebe Chen. "Machine learning for medical imaging-based COVID-19 detection and diagnosis", *International Journal of Intelligent Systems*, 2021.