

# Evaluated the Correlation Between Serum Ferritin and Iron Overload of Liver, Spleen and Heart in $\beta$ -Thalassemia Major Patients by MRI T2\* Method

Nga Thi Ho Nguyen<sup>1</sup>, Phuoc Van Le<sup>1</sup>, Phuoc Thanh Bui<sup>2,\*</sup>, Dung Van Le<sup>1</sup>, Lam Hoang Nguyen<sup>1</sup>, Van Bich Thi Le<sup>1</sup>, Pham Van Bui<sup>1</sup>

<sup>1</sup>Department of Radiology, Cho Ray Hospital, Ho Chi Minh City, Vietnam

<sup>2</sup>Department of Surgery, Pham Ngoc Thach Medical University, Ho Chi Minh City, Vietnam

## Email address:

bs\_thinga@yahoo.com (Nga Thi Ho Nguyen), phuocbvcr@yahoo.com (Phuoc Van Le), phuocphysics123@gmail.com (Phuoc Thanh Bui)

\*Corresponding author

## To cite this article:

Nga Thi Ho Nguyen, Phuoc Van Le, Phuoc Thanh Bui, Dung Van Le, Lam Hoang Nguyen, Van Bich Thi Le, Pham Van Bui. Evaluated the Correlation Between Serum Ferritin and Iron Overload of Liver, Spleen and Heart in  $\beta$ -Thalassemia Major Patients by MRI T2\* Method. *International Journal of Medical Imaging*. Vol. 11, No. 1, 2023, pp. 21-24. doi: 10.11648/j.ijmi.20231101.14

Received: March 17, 2023; Accepted: April 1, 2023; Published: April 18, 2023

**Abstract:**  $\beta$ -Thalassemia major often results in an excess of iron in the body due to frequent blood transfusions and enhanced absorption of iron in the gastrointestinal tract. Early detection of this condition and administering sufficient iron chelator therapy can significantly decrease the risk of complications and fatalities resulting from iron overload. MRI (Magnetic Resonance Imaging) T2\* is an accurate non-invasive method for assessing organ iron overload in  $\beta$ -Thalassaemia major patients. This study evaluated the correlation between serum ferritin and iron overload of liver, spleen, and heart in  $\beta$ -Thalassaemia major patients by MRI T2\* method. The design was a cross-section, descriptive study. We used MRI-T2\* to evaluate the correlation between serum ferritin and iron overload of liver, spleen, and heart in 24 Thalassaemia major patients admitted in Cho Ray hospital from 10/2013 to 1/2014, using a 1.5T MRI system (Siemens) with a body coil. T2\* measurements were taken in the liver, spleen, and myocardium using different gradient echo pulse sequences. T2\* values were calculated within homogeneous regions of interest (ROI) in the liver avoiding major blood vessels, spleen, and the entire thickness of the interventricular septum in the myocardium. Pearson correlation coefficient was used to evaluate correlations in the study with a significance threshold of  $p < 0.05$  using SPSS 16.0 software. As results, moderate negative correlation between serum ferritin and liver, spleen MRI T2\* relaxation time ( $r = 0.57$  and  $0.755$ ) and a weak negative correlation between serum ferritin and heart MRI T2\* relaxation time ( $r = 0.303$ ). Liver and heart MRI T2\* readings were poorly correlated ( $r = 0.28$ ). In conclusion, MRI T2\* is useful to evaluate the iron overload status in  $\beta$  thalassemia patients.

**Keywords:** Serum Ferritin, MRI T2\*,  $\beta$  -Thalassemia Major

## 1. Introduction

$\beta$ -Thalassemia is a common inherited blood disorder caused by a defect in the  $\beta$ -globin chain synthesis gene [20]. Although blood transfusion increases the survival rate of Thalassemia patients, it also increases the risk of iron deposition leading to dysfunction of target organs such as the liver, heart, and endocrine glands [8]. Evaluating iron overload in organs of  $\beta$ -Thalassemia patients is an important issue [7]. Serum ferritin is considered as an indicator of iron

storage in the body, but it is non-specific because its concentration can also increase in other diseases such as hepatitis, cirrhosis, and infections [4]. Which non-invasive laboratory test is reliable for evaluating iron overload in the organs of  $\beta$ -Thalassemia patients? The limitations of serum ferritin and tissues biopsy indicate the need for a non-invasive method with high reliability in assessing iron deposition in organs. T2\*-weighted magnetic resonance imaging (MRI) is a non-invasive method for accurately assessing iron overload in the liver and heart. Therefore, it plays an important role in guiding iron chelation therapy [11,

15, 16, 18]. This method allows early diagnosis of iron overload in the liver and heart and helps to reduce the incidence and mortality rate of Thalassemia patients [1, 2]. The aim of this study was to identify the correlation between serum ferritin and iron overload of liver, spleen, and heart in  $\beta$ -thalassemia major patients by MRI T2\* method.

## 2. Data and Methods

### 2.1. Study Design

Descriptive cross-sectional study.

### 2.2. Location and Time

Department of Diagnostic Imaging - Cho Ray Hospital. The study was conducted from October 2013 to January 2014.

### 2.3. Study Subjects

Patients with  $\beta$ -Thalassemia major undergoing MRI-T2\* evaluation of organ iron overload at Cho Ray Hospital.

Inclusion criteria:  $\beta$ -Thalassemia major patients with serum ferritin measurement within a month when MRI is performed [14].

Exclusion criteria: Patients with poor breath-holding ability during the pulse sequences and images with significant noise on MRI.

### 2.4. Data Collection and Analysis

All patients were evaluated using a 1.5T MRI system (Siemens), using a body coil. T2\* measurements were performed in the liver and spleen using a series of gradient echo pulse sequences during a single breath-hold on a axial (10 mm) slice passing through the mid-liver. T2\* measurements were performed in the myocardium using a GRE pulse sequence along the mid-mediastinum axis. T2\* values were calculated within large regions of interest (ROI) in homogeneous liver and spleen areas, avoiding major blood vessels. In the myocardium, the ROI was the entire thickness of the interventricular septum. Pearson correlation coefficient was used to evaluate correlations in the study with a significance threshold of  $p < 0.05$  using SPSS 16.0 software.

## 3. Results and Discussion

### 3.1. Characteristics of the Study Sample

During the study period from October 2013 to January 2014, 24 patients with  $\beta$ -thalassemia major underwent blood ferritin measurement and magnetic resonance imaging (MRI). Of these patients, 58.3% (14/24) were female, and the average age in the study sample was 21-year-old, with the youngest being 8 years old and the oldest being 51 years old. The characteristics are presented in figures 1 and 2.

The mean liver iron concentration (LIC) in the study was  $17.5 \pm 8.7$  mg/g, with the highest value being 39.4 mg/g and the lowest being 0.2 mg/g. The percentage of patients with Thalassemia major who did not have iron overload in the liver was 8.3%, while

the percentage with moderate iron overload was 25% and the percentage with severe iron overload was 66.7%. In Hankins' study [9], which also used MRI-T2\* to quantify liver iron concentration, the mean value was recorded as  $10.9 \pm 6.8$  mg/g, which is lower than in this study. This difference may be due to the fact that Hankins' study [9] included both thalassemia patients and mainly patients with sickle cell disease.

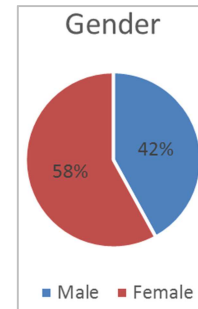


Figure 1. Distribution by gender.

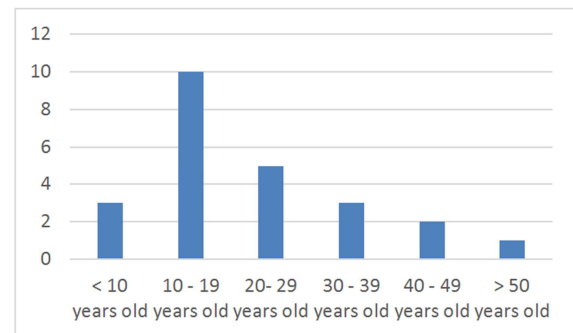


Figure 2. Distribution by age.

The average myocardial iron concentration (MIC) in the study was  $0.6 \pm 2.7$  mg/g ( $T2^* = 34.3 \pm 10.3$  ms); the smallest value was 0.36 mg/g ( $T2^* = 52.2$  ms); the largest value was 2.92 mg/g ( $T2^* = 9.4$  ms). Two cases of iron deposition in the heart were recorded in the study, one of which was related to splenectomy, and both patients had severe iron overload in the liver.

The proportion of patients who underwent splenectomy was 16.6% (4/24). The average splenic iron concentration (SIC) in the study was  $4 \pm 2.6$  mg/g; the highest value was 9.2 mg/g; the smallest value was 0.5 mg/g. In the study, there were four cases of splenectomy, and the remaining cases had splenomegaly. The proportion of normal splenic iron concentration accounted for 25%, and mild iron overload in the spleen accounted for 60%.

In summary, the study sample had 91.7% of patients with iron overload in the liver, 8.4% in the heart, and 75% in the spleen. This reflects the typical pathology of thalassemia, where regular blood transfusions lead to excess iron in the blood, which deposits in internal organs. The liver is the organ most affected proportionally, followed by the spleen, and the most important consequence of iron overload in the heart is heart failure. Therefore, MRI is needed for accurate diagnosis and treatment of iron overload.

The average serum ferritin value was  $2980.7 \pm 2400$  ng/ml;

the highest value was 7838.8 ng/ml, and the lowest value was 2.3 ng/ml. The proportion of patients with high serum ferritin concentrations above 1000 ng/ml was 83.3% (20/24), and

above 2500 ng/ml was. The average serum ferritin value in the study was quite similar to the average value of  $2718 \pm 1994$  ng/ml in the study by Hankins.

**Table 1.** The Iron concentration in Liver (LIC), Myocardium (MIC) and Spleen (SIC).

	LIC	MIC	SIC
Average value	$17,5 \pm 8,7$ mg/g	$0,6 \pm 2,7$ mg/g	$4 \pm 2,6$ mg/g
Lowest value	0,2 mg/g	0,36 mg/g	0,5 mg/g
Highest value	39,4 mg/g	2,92 mg/g	9,2 mg/g
Normal	8,3%	91,7%	25%
Iron overload levels:			
-Mild	0% (2-7mg/g)	0% (1,16-1,65mg/g)	60% (2-7mg/g)
-Moderate	25% (7-15mg/g)	4,2% (1,66-2,71mg/g)	15% (7-15mg/g)
-Severe	66,7% (>15mg/g)	4,2% (>2,71mg/g)	0% (>15mg/g)

### 3.2. The Correlation Between Serum Ferritin and LIC, MIC, SIC

The correlation between serum ferritin concentration and LIC at a moderate level is  $r = 0.57$ , which is quite similar to the results of Azarkeivan [5] with  $r = 0.535$ . However, an important aspect of our study is the very weak correlation between high serum ferritin (>4000 ng/ml) and LIC, same as the results of Worwood [19] and Azarkeivan [5]. In addition, in the study by Hankins [9] with 47 patients comparing the MRI  $T2^*$  method of quantifying LIC with the biopsy method, a moderate correlation of  $r = 0.41$  was found between serum ferritin and LIC, which is analogous to our study. Therefore, the serum ferritin concentration does not reflect the actual iron concentration in the liver in the study population and serum ferritin concentration cannot replace LIC in the assessment of iron overload in the liver [13, 9].

We found a weak correlation between serum ferritin concentration and MIC with a correlation coefficient of  $r = 0.303$ , same as the results of Azarkeivan [5]. This also means that serum ferritin does not accurately reflect the status of iron overload in the myocardium. Therefore, it shows the important role of MRI in evaluating iron overload in the myocardium.

A moderate correlation was observed between serum ferritin concentration and SIC ( $r = 0.755$ ). Similarly, to the correlation between serum ferritin and LIC, we cannot rely on serum ferritin to evaluate the concentration of iron sediment in the spleen.

### 3.3. The Correlation Between MIC and LIC, SIC

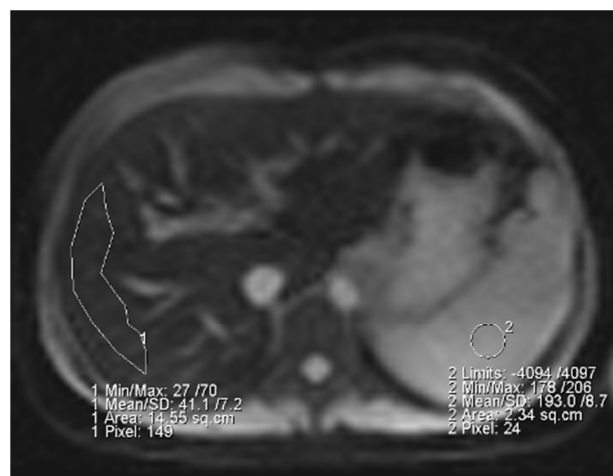The weak correlation between MIC and LIC with  $r = 0.28$  is consistent with the study of Azarkeivan [5]. This may be due to the different mechanisms of iron collection, storage, and excretion of organs. In fact, iron deposition and excretion in the liver are faster than in the heart. And in prolonged iron overload conditions, iron accumulation in the heart is not dependent on whether there is iron overload in the liver. Therefore,  $T2^*$  in the liver cannot reflect the iron overload status in the heart, and it is necessary to measure  $T2^*$  in the heart to evaluate the MIC value [17].

In patients with Thalassemia who receive regular blood transfusions, iron overload in the body can accumulate and negatively affect the liver, heart, endocrine organs, and cause

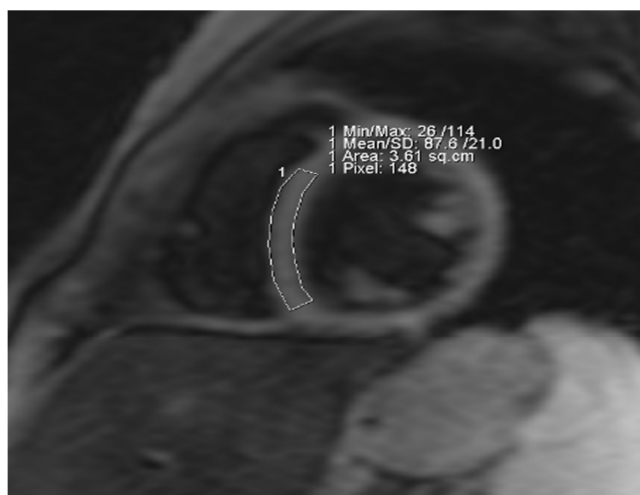
heart failure due to iron toxicity, which is the main cause of increased morbidity and mortality in these patients [10]. Once there are signs of heart failure, the prognosis of death is even higher in this group of patients unless escalated iron removal therapy is applied. However, iron deposited removing in the myocardium is very slow even with the use of enhanced iron removal therapy [10]. Therefore, when a patient has high iron overload concentration in the heart, although the total amount of iron in the body is low, enhanced iron removal therapy is still necessary [17]. Thus, evaluating the iron deposition status in the myocardium in patients with Thalassemia major is essential in the clinical monitoring and treatment process, and it should be performed every 6 months [17]. Currently, MRI is the non-invasive technique of accurately and early diagnosing iron deposition in the myocardium [20].

The study did not record a correlation between MIC and SIC ( $r = 0.192$ ), but in Casey's study [6], it was found that splenectomy in Thalassemia patients increases the risk of iron deposition in the heart. In our study, there were 2 cases of iron deposition in the heart, and 1 case had undergone splenectomy. The amount of iron deposition in the heart in this small sample size did not truly reflect the nature of the relationship between MIC and SIC. Therefore, larger studies are needed to confirm this correlation.

*Illustration of how to measure and evaluate  $T2^*$  in the liver and myocardium.*



**Figure 3.** ROI method on the liver, avoiding  $T2^*$  (Source from the Department of Radiology, Cho Ray Hospital).



**Figure 4.** ROI method on the heart, on T2\* (Source from the Department of Radiology, Cho Ray Hospital).

## 4. Conclusion

Serum ferritin concentration has moderate predictive value for assessing iron overload in the liver and spleen but has low predictive value for assessing iron overload in the myocardium of patients with  $\beta$ -thalassemia major. The weak correlation between myocardial iron concentration (MIC) and liver iron concentration (LIC), and the important pathological nature of iron overload in the heart causing cardiac failure, emphasizes the need for direct assessment of cardiac iron concentration using T2\* MRI. Therefore, we suggest routine T2\* MRI in thalassemia patients to evaluate iron deposition in the liver and heart instead of relying solely on serum ferritin. However, this study is limited by the sample size not being large enough to observe the correlation between splenectomy and iron overload in the heart. In the future, it is necessary to determine and quantify the iron concentration in liver tissue in patients with liver fibrosis because iron deposition increases the risk of hepatocellular carcinoma [3].

## References

- [1] Anderson LJ. Assessment of iron overload with T2\* magnetic resonance imaging. *Progress in cardiovascular Diseases*, 2011, 54: 287-294.
- [2] Anderson LJ et al. Cardiovascular T2\* magnetic resonance for early diagnosis of myocardial iron overload. *European Heart Journal*, 2001, 22: 2171-2179.
- [3] Andrew T2\*: an ROC study. *The Internet Journal of Gastroenterology*, 2009, 8 (2): 1528-1532.
- [4] Argyropoulou MI, Astrakas L. MRI evaluation of tissue iron burden in patients with  $\beta$  - Thalassemia major. *Pediatric Radiology*, 2007, 37: 183-190.
- [5] Azarkeivan A et al. Relation between serum ferritin and liver and heart MRI T2\* in  $\beta$  thalassaemia major patients. *Eastern Mediterranean Health Journal*, 2012, 19: 727-380.
- [6] Casey J. Brewer et al. Spleen R2 and R2\* in iron-overload patients with sickle cell disease and thalassemia major. *J Magn Reson Imaging*, 2009, 29 (2): 357-364.
- [7] Cohen AR et al. Thalassemia. *Hematology* (American society of Hematology Education Program). Washington DC, American Society of Hematology, 2004: 14-34.
- [8] Hamed EA, El Melegly NT. Renal functions in pediatric patients with  $\beta$  - thalassemia major: relation to chelation therapy: original prospective study. *Italian Journal of Pediatrics*, 2010, 6: 39.
- [9] Jane S Hankins, et al. R2\* magnetic resonance imaging of the liver in patients with iron overload. *Blood*, 2009, 113: 4853-4857.
- [10] Jonh-Paul Carpenter, et al. On T2\* magnetic resonance and cardia citron. *Circulation*, 2011, 1519-1528.
- [11] Kirk P et al. International reproducibility of single breath hold T2\* MR for cardiac and liver iron assessment among five thalassemia centers. *Journal of Magnetic Resonance Imaging*, 2010, 32: 315-319.
- [12] Kirk P et al. Cardiac T2\* magnetic resonance for the prediction of cardiac complications in thalassemia major. *Circulation*, 2009, 120: 1961-1968.
- [13] Leung AW et al. Magnetic resonance imaging assessment of cardiac and liver iron load in transfusion depend patients. *Pediatric blood and cancer*, 2009, 53: 1054-1059.
- [14] Ping Hou et al. A practical approach for a wide range of liver iron quantitation using a magnetic resonance imaging technique. *Radiology research and practice*, 2012, 2012: 2073-2082.
- [15] St pierre TG et al. Noninvasive measurement and imaging of liver iron concentrations using proton magnetic resonance. *Blood*, 2005, 105: 855-861.
- [16] Tanner MA et al. Thalassemia International Federation Heart T2\* Investigators. Multi-center validation of the transferability of the magnetic resonance T2\* technique for the quantification of tissue iron. *Hematological*, 2006, 91: 1388-1391.
- [17] Wood JC. Diagnosis and management of transfusion iron overload: the role of imaging. *PMC*, 2010, 82: 1132-1135.
- [18] Wood JC. Magnetic resonance imaging measurement of iron overload. *Current Opinion Hematology*, 2007, 14: 183-190.
- [19] Worwood M et al. Binding of serum ferritin to concanavalin A: patients with homozygous  $\beta$  thalassaemia and transfusion iron overload. *British Journal of Haematology*, 1980, 46: 409-416.
- [20] Yesilipek MA. Stem cell transplantation in hemoglobinopathies. *Hemoglobin*, 2007, 31: 251-256.